Galway University Hospitals
Ospidéil na h-Ollscoile Gaillimh
UNIVERSITY HOSPITAL GALWAY
MERLIN PARK UNIVERSITY HOSPITAL

20W141

Saolta
Grúpa Ollscoile Cúram Sláinte
University Health Care Group

SMALL BOWEL CAPSULE ENDOSCOPY IN THE WEST OF IRELAND: A CLOSER LOOK AT THE FIRST YEAR

O'Donovan H, Madders G, Hassan Y, Gallagher D, Goulding C

INTRODUCTION

The small bowel is the least common site of blood loss from the gastrointestinal (GI) tract but the commonest site of obscure GI bleeding. Blood loss from the GI tract is the most common cause of iron deficiency anaemia (IDA) in men and postmenopausal women. In those with persistent IDA post endoscopic investigation, adequate iron replacement and management of other potential underlying causes (i.e. NSAID use), small bowel capsule endoscopy (SBCE) or enteroscopy are crucial tools for further investigation and diagnosis. In fact The European Society of Gastrointestinal Endoscopy (ESGE) recommends SBCE as the first line investigation in patients with obscure GI bleeding. SBCE is also indicated to assist in the diagnosis of small bowel Crohn's disease.

METHODS

This is a retrospective review of all SBCE performed in University College Hospital Galway (UCHG) since the introduction of the service in March 2019 to July 2020. All patients who had completed SBCE during this time were included. Data were collected from Pilcam studies. Demographics, indication for procedure and outcome were recorded. Quality of bowel preparation and transit time were also analysed. The use of anticoagulation or antiplatelet therapy was recorded.

RESULTS

In total, 122 patients underwent SBCE during the study period. There were 60 women and 62 men with a median age of 58.5 years. Most referrals were from the Gastroenterology outpatients department (49%), 32% from other hospitals and 18% were inpatients in UCHG. The preparation was adequate in 85% of cases and the median small bowel transit time was 240 minutes.

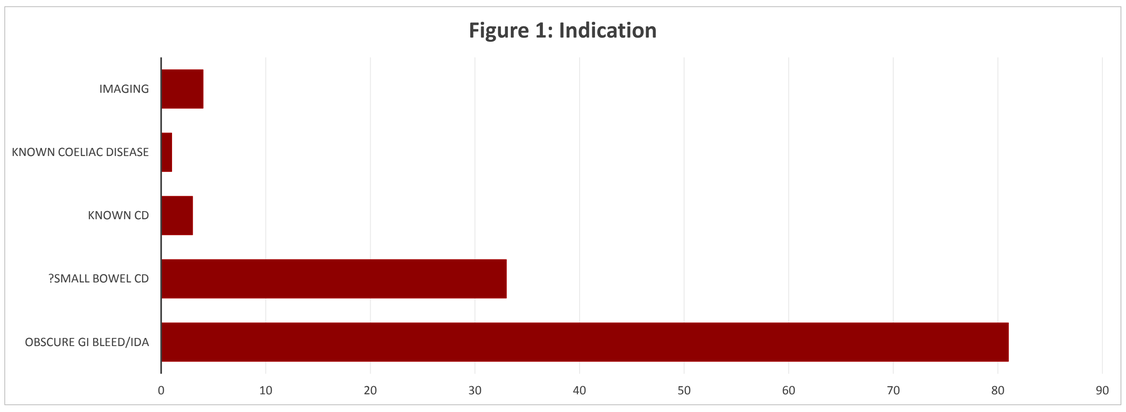

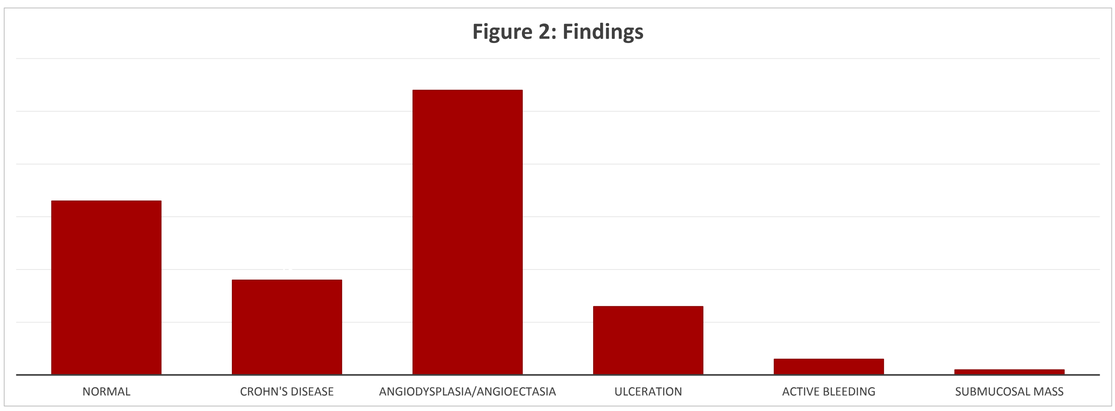

Of the 81 patients referred for obscure GI bleeding or IDA, 52 (64%) were found to have angiodysplasia/angioectasia. Of those, 27 (52%) were taking anticoagulant/antiplatelet therapy. 36 patients were referred for diagnosis or assessment of small bowel Crohn's disease with 13 (33%) of these having positive findings.

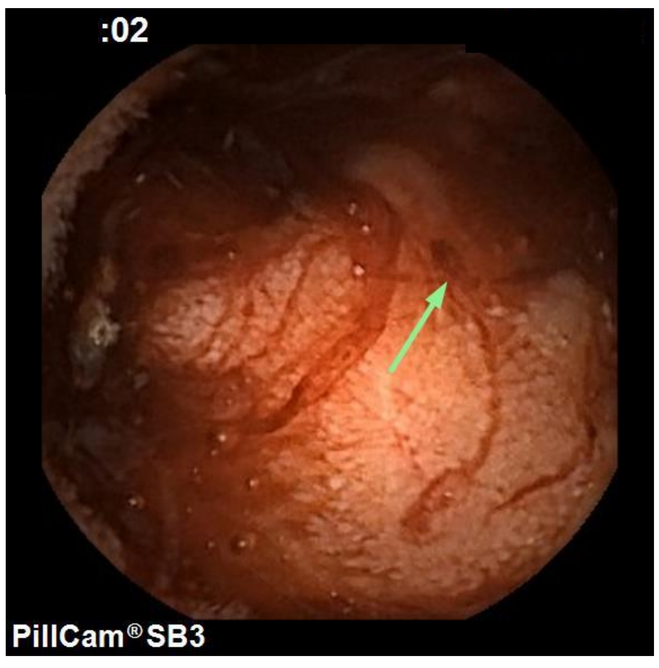

Image 1: Angiodysplasia with active bleeding

Image 2: Crohn's disease

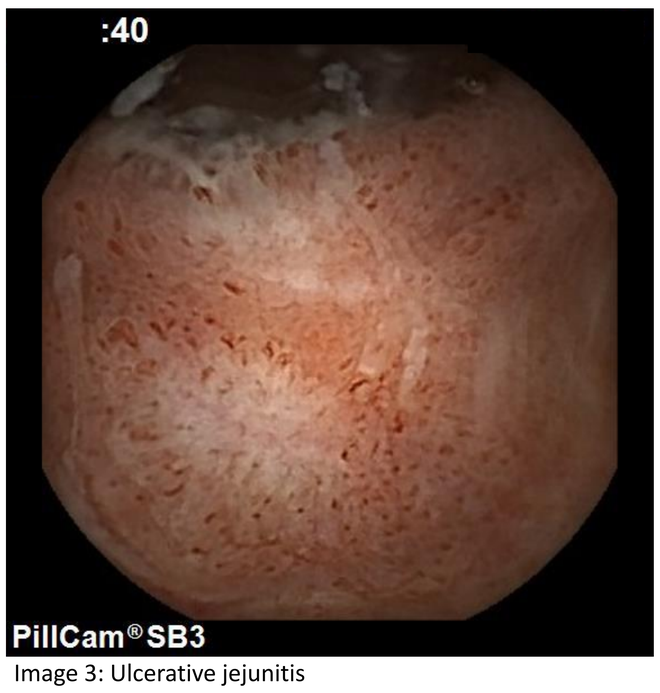

Image 3: Ulcerative jejunitis

CONCLUSIONS

The introduction of SBCE in our centre has proven to be a useful addition for investigation of obscure GI bleeding and other small bowel pathology with positive findings detected in two thirds of the patients. It can be performed in an outpatient setting and has a very high completion rate. The use of anticoagulant/antiplatelet therapy may increase the risk of obscure GI bleeding/IDA due to angiodysplasia.

References
https://www.esge.com/enterosocopy-and-small-bowel-endo/
https://www.bsg.org.uk/clinical-resource/guidelines-for-the-management-of-iron-deficiency-anaemia/